

Mesenchymal Stem Cell Injections Improve Symptoms of Knee Osteoarthritis

Yong-Gon Koh, M.D., Seung-Bae Jo, M.D., Oh-Ryong Kwon, M.D., Dong-Suk Suh, M.D.,
Seung-Woo Lee, M.D., Sung-Ho Park, M.D., and Yun-Jin Choi, M.D.

Purpose: The purpose of this study was to evaluate the clinical and imaging results of patients who received intra-articular injections of autologous mesenchymal stem cells for the treatment of knee osteoarthritis. **Methods:** The study group comprised 18 patients (6 men and 12 women), among whom the mean age was 54.6 years (range, 41 to 69 years). In each patient the adipose synovium was harvested from the inner side of the infrapatellar fat pad by skin incision extension at the arthroscopic lateral portal site after the patient underwent arthroscopic debridement. After stem cells were isolated, a mean of 1.18×10^6 stem cells (range, 0.3×10^6 to 2.7×10^6 stem cells) were prepared with approximately 3.0 mL of platelet-rich plasma (with a mean of 1.28×10^6 platelets per microliter) and injected into the selected knees of patients. Clinical outcome was evaluated with the Western Ontario and McMaster Universities Osteoarthritis Index, the Lysholm score, and the visual analog scale (VAS) for grading knee pain. We also compared magnetic resonance imaging (MRI) data collected both preoperatively and at the final follow-up. **Results:** Western Ontario and McMaster Universities Osteoarthritis Index scores decreased significantly ($P < .001$) from 49.9 points preoperatively to 30.3 points at the final follow-up (mean follow-up, 24.3 months; range, 24 to 26 months). Lysholm scores also improved significantly ($P < .001$) by the last follow-up visit, increasing from a mean preoperative value of 40.1 points to 73.4 points by the end of the study. Likewise, changes in VAS scores throughout the follow-up period were also significant ($P = .005$); the mean VAS score decreased from 4.8 preoperatively to 2.0 at the last follow-up visit. Radiography showed that, at the final follow-up point, the whole-organ MRI score had significantly improved from 60.0 points to 48.3 points ($P < .001$). Particularly notable was the change in cartilage whole-organ MRI score, which improved from 28.3 points to 21.7 points ($P < .001$). Further analysis showed that improvements in clinical and MRI results were positively related to the number of stem cells injected. **Conclusions:** The results of our study are encouraging and show that intra-articular injection of infrapatellar fat pad-derived mesenchymal stem cells is effective for reducing pain and improving knee function in patients being treated for knee osteoarthritis. **Level of Evidence:** Level IV, therapeutic case series.

Recently, mesenchymal stem cells (MSCs) have been suggested for use in the cell-based treatment of cartilage lesions. These cells show great potential as therapeutic agents in regenerative medicine because of their multilineage potential, immunosuppressive activities, limited immunogenicity, and relative ease of growth in culture.¹ Although ethical and political issues

surround the use of embryonic stem cells, the use of MSCs is generally well accepted by society. Furthermore, MSCs are an autologous source of cells, eliminating concerns regarding rejection and disease transmission, and they are less tumorigenic than their embryonic counterparts.²

The transplantation of MSCs into full-thickness articular cartilage defects has been attempted under various conditions in vivo. For example, Murphy et al.³ used direct intra-articular injection to deliver adult stem cells isolated from caprine bone marrow into injured knees. They reported that degeneration of the articular cartilage and subchondral sclerosis were reduced in cell-treated joints compared with joints treated with vehicle alone without cells. Furthermore, there have been several studies on human patients reporting good outcomes within 6 months of intra-articular injection of autologous MSCs.^{4,5} In 2008 Centeno et al.⁵ described a technique for using autologous culture-expanded bone marrow-derived stem cells for regeneration of

From the Center for Stem Cell & Arthritis Research, Department of Orthopedic Surgery (Y-G.K., S-B.J., O-R.K., D-S.S., Y-J.C.), and Department of Radiology (S-W.L., S-H.P.), Yonsei Sarang Hospital, Seoul, South Korea.

Y-G.K. and S-B.J. contributed equally to this work.

The authors report that they have no conflicts of interest in the authorship and publication of this article.

Received July 14, 2012; accepted November 13, 2012.

Address correspondence to Yun-Jin Choi, M.D., Center for Stem Cell & Arthritis Research, Department of Orthopaedic Surgery, Yonsei Sarang Hospital 478-3, Bangbae-dong, Seocho-gu, Seoul, South Korea. E-mail: yunjinchoi78@gmail.com

© 2013 by the Arthroscopy Association of North America
0749-8063/12466/\$36.00

<http://dx.doi.org/10.1016/j.arthro.2012.11.017>

knee cartilage in humans. Patients who underwent this treatment had improvements in both visual analog scale (VAS) scores and range of motion, and magnetic resonance imaging (MRI) showed significant articular cartilage growth and meniscus regeneration. More recently, Buda et al.⁶ advocated the use of a one-step technique in repairing osteochondral lesions of the knee with bone marrow-derived mesenchymal stem cell (BMSC) transplantation. When this technique was used to repair osteochondral knee lesions, outcomes closely resembled those obtained with autologous chondrocyte implantation in similar lesions. Although there are many reports of successful outcomes, the clinical application of these cells remains limited by the number of questions still surrounding their use. To date, there have been very few clinical studies on MSC transplantation for cartilage repair; however, results from animal experiments on the use of MSCs for the prevention and treatment of experimental osteoarthritis (OA) are encouraging.^{3,7-9}

In our previous study of 1-year follow-up results of infrapatellar fat pad-derived MSC therapy with intra-articular injections, we found that MSC therapy in patients with knee OA is not only safe but also helps reduce pain and improve function.¹⁰ A significant weakness of our prior research was that there was no objective surveillance of MSC injection efficacy at any follow-up point. In this article, however, we report the results of 2 years of follow-up to that study. Specifically, we present clinical and imaging results of a series of 18 consecutive patients who received MSC therapy. We hypothesized that this novel intra-articular injection of infrapatellar fat pad-derived MSCs would be effective for reducing pain and improving knee function in patients being treated for knee OA.

Methods

Study protocols were approved by our ethics committee, and all patients provided written informed consent. We retrospectively reviewed the records of 33 patients who underwent stem cell therapy for OA between January and September 2010. All individuals were treated by a single surgeon (Y-G.K.). Eligible patients were aged 40 years or older and had been diagnosed with idiopathic or secondary knee OA (Kellgren-Lawrence grade 3 OA in multiple compartments or grade 4 OA in only one compartment, including the medial or lateral compartments of the tibiofemoral joint or the patellofemoral compartment¹¹). Patients were excluded if they met at least one of the following criteria: diagnosis with Kellgren-Lawrence grade 4 OA in 2 compartments (the medial or lateral compartments of the tibiofemoral joint or the patellofemoral compartment),¹¹ diagnosis with inflammatory or postinfectious arthritis, previous arthroscopic treatment for knee OA, varus or valgus deformity of 5° or

more, previous major knee trauma, intra-articular corticosteroid injection in the preceding 3 months, major neurologic deficits, large meniscal (bucket-handle) tears, and inability to provide informed consent. This left us with a sample size of 25 patients. However, we were unable to examine 2 patients at the final follow-up (i.e., we had follow-up loss because they did not want to visit our hospital), and 5 more patients could only be examined incompletely (because they did not want to undergo MRI examination).

Surgical Procedure and MSC Harvesting Technique

After receiving spinal anesthesia, patients underwent arthroscopic treatment performed with the use of a tourniquet. The orthopaedic surgeon evaluated the medial, lateral, and patellofemoral joint compartments; graded articular lesions according to the International Cartilage Repair Society (ICRS) Cartilage Injury Evaluation Package; irrigated the compartment with at least 1 L of saline solution; and performed one or more of the following treatments: synovectomy, debridement, or excision of degenerative tears of the menisci, fragments of articular cartilage, chondral flaps, or osteophytes that prevented full extension. The surgeon did not perform abrasion or microfracture of chondral defects.

Patients were restricted from consuming corticosteroids or nonsteroidal anti-inflammatory drugs for 1 week before the infrapatellar fat pad harvesting procedure. Fat pads were collected immediately after arthroscopic surgery. This was followed by arthroscopic surgery to harvest adipose synovium from the inner side of the infrapatellar fat pad by extending the skin incision at the arthroscopic lateral portal site (Fig 1). The infrapatellar fat pad was then collected (mean weight, 9.1 g; range, 6.4 to 13.1 g), after which MSCs were derived and counted with a hemocytometer, as described previously.^{10,12,13}

After the stem cells were isolated, a mean of 1.18×10^6 stem cells (range, 0.3×10^6 to 2.7×10^6 stem cells) were prepared with approximately 3.0 mL of platelet-rich plasma (PRP) and injected into the selected knees of the study participants. Because stem cell preparation takes only 3 to 4 hours, the first injection could be performed on the same day as the arthroscopic operation. The skin was dressed under aseptic conditions, and the injection was performed through a classic lateral approach of the upper pole of the patella with a 22-gauge needle. Before injection, the knee was aspirated for hemarthrosis, and no steroid was injected in the knee joint. The first injection was performed in a general ward, and the other injections were performed in an outpatient setting. At the end of the procedure, the patient was invited to bend and extend the knee a few times to allow the stem cell preparation to distribute throughout the joint before becoming a gel. After the injection, patients were sent

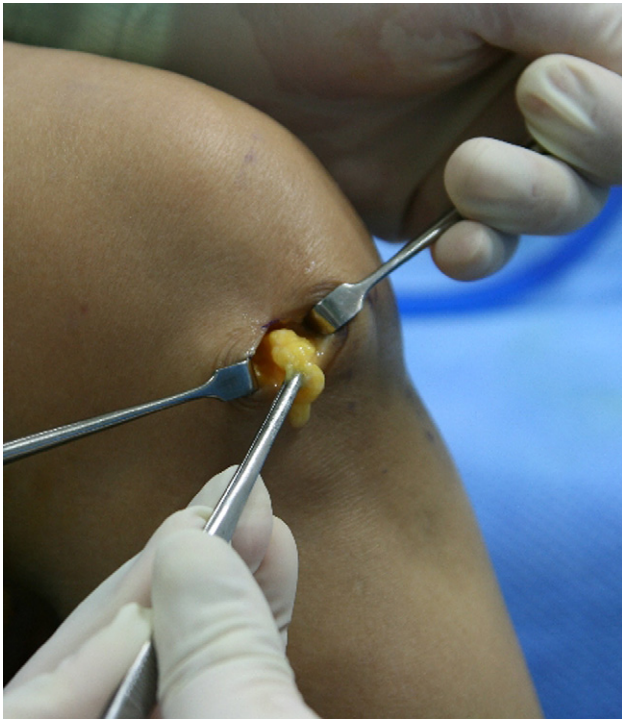

Fig 1. Adipose synovium was harvested from the infrapatellar fat pad by extension of the arthroscopic lateral portal site.

home to apply cold therapy/ice to the affected area for pain.

Rehabilitation

We did not use a formal rehabilitation program. Walking was not restricted during the treatment period, and in fact, we urged patients to engage in mild activities (e.g., exercise biking and pool-based exercises). Subsequently, gradual resumption of normal sports or recreational activities was allowed as tolerated. No analgesics, anti-inflammatory drugs, or immunosuppressive drugs were administered or allowed after the procedure. For the second and third rounds of treatment, patients were injected with an additional 3 mL of PRP at 7 and 14 days after the first injection, respectively (as described later).

PRP Technique

For PRP preparation, a 60-mL venous blood sample (placed in a bag containing 4 mL of sodium citrate) was collected for every lesion treated. The complete peripheral blood count was determined by use of the first blood sample collected. Samples were then centrifuged twice (at 1,800 rpm for 15 minutes to separate the erythrocytes and then at 3,500 rpm for 10 minutes to concentrate the platelets) to yield 6 mL of PRP. The PRP was divided into 2 units of 3 mL each. The total number of platelets per milliliter in the PRP represented a mean increase of 500% compared with whole blood values, and a mean of 1.28×10^6 platelets

per microliter was distributed at the lesion site during every injection. Calcium chloride was added to the PRP unit before each injection to activate the platelets. All procedures were performed in the same laboratory setting, and all open procedures were performed in an A-class sterile hood.

Patient Assessment

A retrospective assessment was performed on data extracted from the arthroscopic surgery database and from patients' medical records. Clinical outcome was evaluated with the Western Ontario and McMaster Universities Osteoarthritis Index (WOMAC), the Lysholm score,¹⁴ and the VAS for grading knee pain. On the 10-mm VAS, scores for pain, ranging from 0 (no pain) to 10 (worst possible pain),¹⁵ were recorded. Patients were evaluated preoperatively, at 3 months and 1 year postoperatively, and at the last follow-up visit (mean, 24.3 months; range, 24 to 26 months).

We used the whole-organ MRI score (WORMS) to perform whole-organ knee evaluation. This semi-quantitative, multifeature scoring method is applicable to conventional, widely available MRI techniques. Two musculoskeletal radiologists (S-W.L. and S-H.P.) independently assigned scores to MRI studies that had been transferred to picture archiving and communication system workstations.¹⁶ Images for all 18 MRI studies were scored with respect to 14 independent articular features: cartilage signal and morphology, subarticular bone marrow abnormality, subarticular cysts, subarticular bone attrition, marginal osteophytes, medial and lateral meniscal integrity, anterior and posterior cruciate ligament integrity, medial and lateral collateral ligament integrity, synovitis, loose bodies, and periarticular cysts or bursae. The final WORMS (Table 1) was tabulated as follows: (1) independent values of each feature in each of the 3 compartments of the knee (patellofemoral joint, medial femorotibial joint, and lateral femorotibial joint), (2) cumulative surface feature scores (cartilage, marrow abnormality, subarticular cysts, bone attrition, and osteophytes) of each compartment, (3) cumulative scores of each feature throughout the knee, and (4) a total combined score for the entire knee.¹⁶ We were particularly interested in using cartilage signals and morphology scores to determine the chondrogenic effects of stem cells on each of the focal features.

Preoperative and final follow-up MRI was performed on a 1.5-T MRI unit (Achieva 1.5-T SE; Philips, Eindhoven, Netherlands). MRI of the study knee of each patient was performed with a 1.5-T whole-body scanner and a commercial circumferential 8-channel knee coil. Proton density (with and without fat suppression) and T2-weighted fast spin-echo images were acquired in the sagittal, frontal, and transverse planes. The total time required for MRI, including patient setup, was 30 minutes. All images were visually

Table 1. Maximum Scores Attainable With WOMMS

Variable	MFTJ	LFTJ	PFJ	S Region	Total
Cartilage	30	30	24		84
Marrow abnormality	15	15	12	3	45
Bone cysts	15	15	12	3	45
Bone attrition	15	15	12		42
Osteophytes	35	35	28		98
Menisci	6	6			12
Ligaments					3
Synovitis					3
Total					332

LFTJ, lateral femorotibial joint; MFTJ, medial femorotibial joint; PFJ, patellofemoral joint; S region, non-articulating portion of tibial plateau beneath tibial spines.

inspected for quality. In case of poor quality, repeat images were acquired within 10 days.

Statistical Analysis

All data are expressed as means and standard deviations. Wilcoxon signed rank tests and Mann-Whitney *U* tests were used to analyze statistical differences between preoperative and follow-up values of WOMAC scores, Lysholm scores, VAS pain scores, and WOMMS. Spearman correlation coefficients were used to assess correlations between continuous variables. For all tests, significance was defined as $P < .05$. All statistical analyses were performed with SPSS software, version 12.0 (IBM, Armonk, NY).

Results

Our final sample size was 18 patients (6 men and 12 women); the mean age was 54.6 years (range, 41 to 69 years). The mean follow-up period was 24.3 months (range, 24 to 26 months) (Table 2). We performed one or more of the following treatments: gentle synovectomy ($n = 5$), excision of degenerative tears of the menisci ($n = 7$), removal of fragments of articular cartilage or chondral flaps ($n = 7$), and removal of osteophytes that prevented full extension ($n = 3$). We did not perform abrasion or microfracture of chondral defects.

WOMAC scores decreased substantially over the study period. The mean score was 49.9 points preoperatively, but this decreased to 38.3 points at the 1-year evaluation and to 30.3 points at the final follow-up. The differences between the preoperative WOMAC score and those obtained at the last follow-up points after

Table 2. Patient Demographics and Treatment Details

	Data
Age (mean \pm SD) (yr)	54.6 \pm 7.8
Follow-up (mean \pm SD) (mo)	24.3 \pm 0.8
ICRS cartilage grade (mean \pm SD)	3.8 \pm 0.4
Sex (male/female)	6/12
Injected stem cells (mean \pm SD) ($\times 10^6$)	1.18 \pm 0.69

NOTE. Boldface indicates pertinent results.

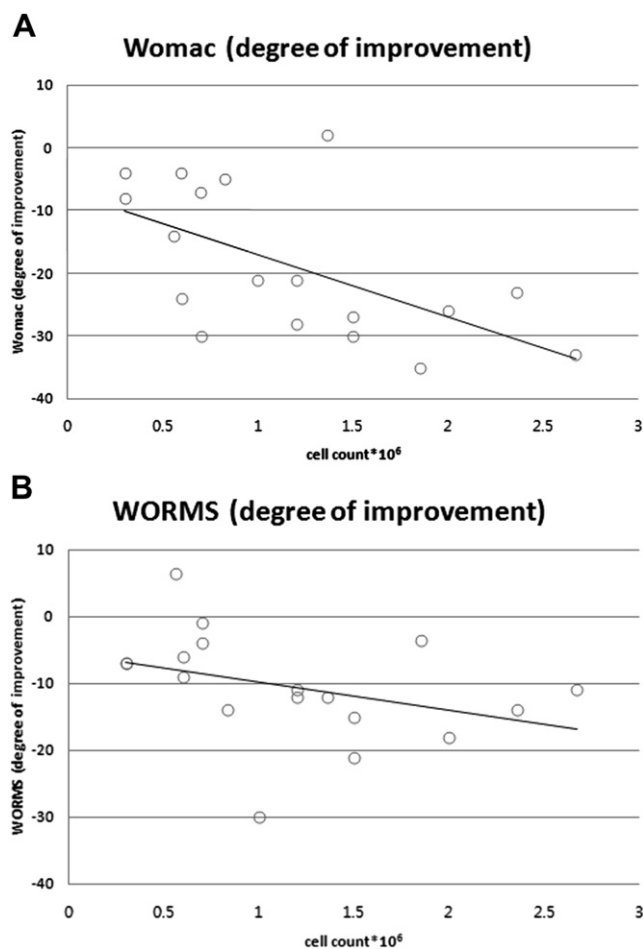


Fig 2. Correlations between patient outcomes and number of stem cells injected. (A) The negative correlation between WOMAC score and number of cells injected indicates that treatment with larger quantities of stem cells results in improved outcomes. (B) The negative correlation between the WOMMS cartilage subscore and the number of stem cells injected suggests that improved outcomes are the result of treatment with larger quantities of stem cells.

the stem cell injections were statistically significant ($P < .001$). Improvements were notably greater in patients with ICRS grade 3 OA (30.6 points) than in those with ICRS grade 4 (15.0 points) ($P = .005$). Changes in WOMAC score were positively related to the number of cells injected ($r = -0.588$, $P = .011$), indicating that treatment efficacy improved with increases in the number of cells injected (Fig 2A).

Lysholm scores also improved significantly ($P < .001$) by the last follow-up visit, increasing from a mean preoperative value of 40.1 points to 73.4 points by the end of the study. Likewise, changes in VAS scores throughout the follow-up period were significant ($P = .005$) (Table 3); the mean VAS score decreased from a preoperative value of 4.8 to 2.0 at the last follow-up visit.

The control MRI study at the last follow-up visit showed an important improvement of the cartilaginous

Table 3. Clinical Outcome Assessment of Patients Treated With MSCs

	Preoperative Status (Mean ± SD)	Last Follow-up (Mean ± SD)	P Value*
WOMAC score	49.9 ± 12.6	30.3 ± 9.2	<.001
Lysholm score	40.1 ± 12.1	73.4 ± 13.5	<.001
VAS score	4.8 ± 1.6	2.0 ± 1.1	<.001

NOTE. Boldface indicates pertinent results.

*Determined by Wilcoxon signed rank test.

tissue in the different parameters of the WOMRS. The WOMRS improved significantly ($P < .001$) over the study period, from a mean preoperative value of 60.0 points to a value of 48.3 points at the last follow-up visit (Table 4). Particularly notable was the reduction in the cartilage subscore, which fell from a mean preoperative value of 28.3 points to 21.7 points at the last follow-up visit ($P < .001$). As with the WOMAC scores, greater improvements were seen in individuals in whom larger numbers of cells were injected ($r = -0.536$, $P = .002$) (Fig 2B). The postoperative MRI studies of one 45-year-old female patient showed particularly notable changes in cartilage defects of the medial femoral condyle (Fig 3).

No complications, either intraoperative or postoperative, were observed in this series. In some cases slight pain was experienced in the first 2 to 3 days after the injection; however, only one patient had adverse events related to the injections. In this case the patient had marked pain with swelling after the injection, and these symptoms resolved spontaneously after 2 weeks. The etiology of the marked pain is unclear, but because previous patients reported only slight pain when injected with PRP only, we hypothesize that the MSCs must have been responsible for the marked discomfort. Both the pain and the swelling had receded (to at least half their previous levels) by the second injection time, and so the patient proceeded with the remainder of the treatment.

Discussion

This study was performed as a follow-up to previous work in which we evaluated the safety of a novel OA therapeutic technique.¹⁰ In that study we examined MSC therapy in the same 25 patients to determine whether it was safe; however, we were not able to show

Table 4. WOMRS Assessment of Patients Treated With MSCs

	Preoperative Status (Mean ± SD)	Last Follow-up (Mean ± SD)	P Value*
WORMS	60.0 ± 33.0	48.3 ± 31.8	<.001
WORMS cartilage score	28.3 ± 11.7	21.7 ± 10.3	<.001

NOTE. Boldface indicates pertinent results.

*Determined by Wilcoxon signed rank test.

that MSC therapy is effective. In the current study, we used both clinical assessments and MRI to determine that MSC therapy, during which MSCs are intra-articularly injected into the knee, is an effective way to reduce pain and improve function in patients with knee OA. Furthermore, treatment outcome appears to be positively related to the number of cells injected, and results after 2 years were better than short-term results. This is promising given our previous observations that the treatment does not result in any major complications (e.g., infection, marked muscle atrophy, fever, hematoma, tissue hypertrophy, or adhesion formation). We acknowledge that the arthroscopic procedure could be at least partly responsible for the improved clinical outcomes. However, arthroscopic debridement has only very short-term effects in patients with advanced knee OA¹⁷; the WOMAC scores of our patients indicated that improvements lasted well over 2 years (to at least the final follow-up at 24 to 26 months). This indicates that stem cell therapy improves knee function over time. If the arthroscopic procedure is the main reason why we saw improvements in outcome, then clinical outcome changed for the worse as time went on.

Transplantation of MSCs for the treatment of articular cartilage defects has been attempted under various conditions.^{6,18} For example, McIlwraith et al.¹⁸ investigated whether intra-articular injection of BMSCs augmented healing in equine microfractures. They found that intra-articular BMSCs enhance cartilage repair quality by increasing aggrecan content and tissue firmness, and this finding is supported by our current results. On the other hand, Buda et al.⁶ reported that osteochondral lesions of the knee (and similar lesions) can be treated with similar effectiveness with both bone marrow-derived stem cells and autologous chondrocyte implantation. However, whereas Buda et al. used BMSCs and focused only cartilage defects, we used adipose tissue-derived MSCs and focused not only on cartilage but on the whole knee joint.

In this study we used a PRP scaffold because it acts as an MSC accelerator for clinical chondrogenesis.^{19,20} PRP is nonimmunogenic and bioabsorbable and can be easily prepared preoperatively. Recent research has indicated that treatment with PRP injections not only is safe but also has the potential to reduce pain and improve knee function and quality of life in patients with degenerative osteoarthritis of the knee.²¹ Because the average baseline blood platelet count of an individual is $2 \times 10^5 \pm 7.5 \times 10^4/\mu\text{L}$, a platelet count of $1 \times 10^6/\mu\text{L}$ (5-fold greater than the average) is commonly used for therapeutic platelet-rich preparations.²² We administered a mean of 1.28×10^6 platelets per microliter during each injection.

Although BMSCs in general have been studied widely,²³ there has only been limited research on the use of human autologous bone marrow stromal cell

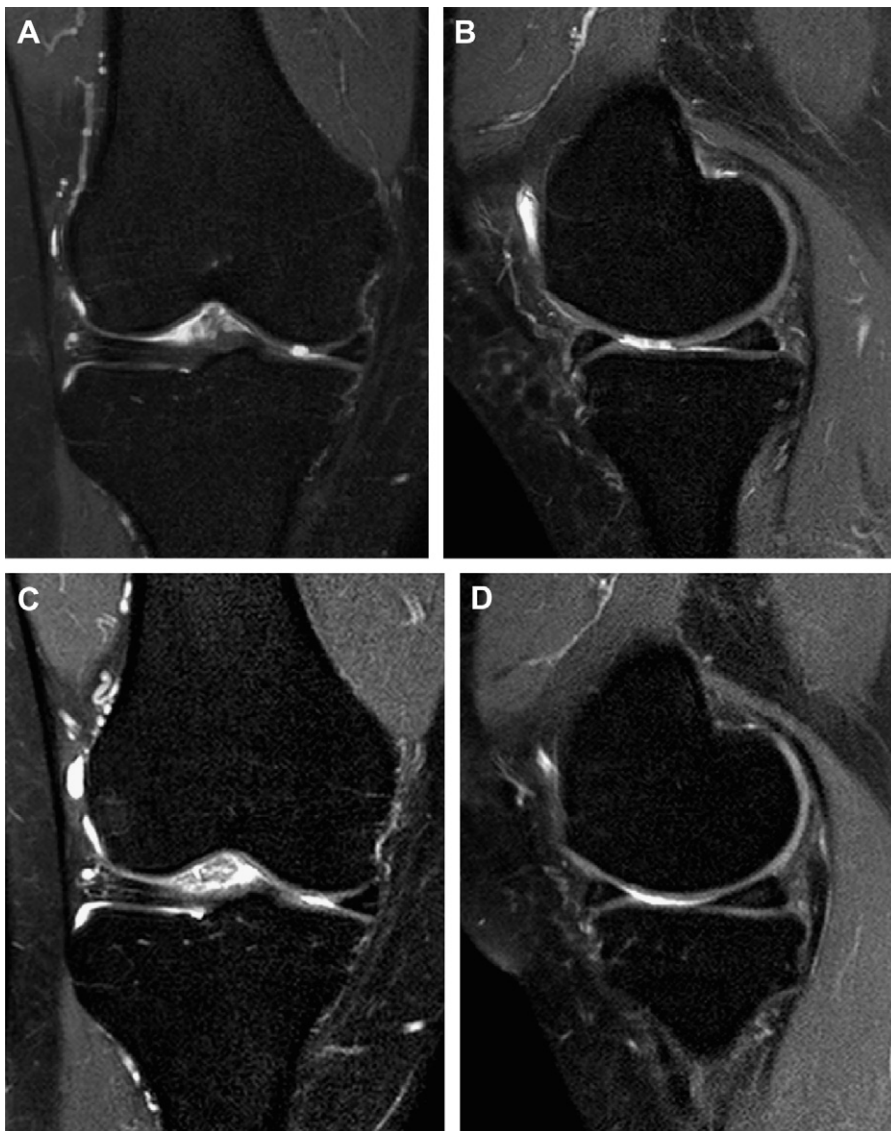


Fig 3. Results of MRI performed preoperatively (A and B) and postoperatively (C and D) on a 45-year-old female patient. This MRI is not representative of all MRIs observed in the study but is explored in further detail because the effects of the treatment were particularly dramatic in this patient. (A) Fat-saturated proton-density fast spin-echo coronal view and (B) T1-weighted fast spin-echo sagittal view of osteochondral defects of medial femoral condyle. (C) Fat-saturated proton-density fast spin-echo coronal view and (D) gradient-echo sagittal view of same patient at 2-year follow-up visit.

implantation for cartilage repair.^{6,24} Unfortunately, bone marrow harvesting is painful and is associated with donor-site morbidities and risks of wound infection and sepsis.²⁵ In addition, because bone marrow contains relatively small numbers of MSCs (approximately 1/10,000 to 1/100,000 per nucleated cell),²⁵ ex vivo expansion is required before bone marrow can be used therapeutically in a clinical setting. MSC concentrations in adipose tissue, on the other hand, are approximately 100- to 1,000-fold higher (approximately 50/mL to 100,000/mL).²⁶ Moreover, the yield of adherent colony-forming cells is reportedly higher from the infrapatellar fat pad than from bone marrow: A 30-mL bone marrow aspirate generates approximately 1×10^5 cells,²⁷ whereas 21 mL of the infrapatellar fat pad yields approximately 5.5×10^6 cells.²⁸ Thus we chose the infrapatellar fat pad as a source of MSCs for use in cartilage defect treatment.

In an experimental animal model of OA, Toghraie et al.²⁹ used direct intra-articular injection to introduce scaffold-free MSCs, obtained from the infrapatellar fat pad, into the knees of rabbits. The cells had been expanded and grown in vitro and were delivered 12 weeks after the operation in a single dose of 1 million cells suspended in 1 mL of medium. Twenty weeks after surgery, rabbits that received MSCs had less cartilage degeneration, osteophyte formation, and subchondral sclerosis than did those in the control group. Moreover, the cell-treated rabbits had higher-quality cartilage. On the basis of these results, the authors concluded that infrapatellar fat pads were a promising source of MSCs for use in the treatment of OA. Despite these obvious successes, it is important to note that the mechanisms by which MSC therapy facilitates tissue repair are still unknown. For example, it is unclear whether the injected MSCs regenerate

degenerative tissue after directly filling the lesion or whether they indirectly stimulate the secretion of bioactive factors such as cytokines and growth factors. Further research is clearly needed on this topic.

Tissue-engineering techniques hold promise for repairing damaged joint cartilage. However, several challenges still need to be overcome to optimize cell-based tissue repair therapies in our aging population. First and foremost is identification of a stem cell source that maximizes simplicity of extraction and cell yield, produces cells whose proliferation and differentiation potentials do not decline with age, and is associated with a low risk of complications. It will also be important to determine the optimal source of scaffolds and growth factors. Our research is an important first step in this process; our positive clinical and radiologic outcomes suggest that further randomized controlled clinical trials of this treatment modality, involving a larger number of patients and a longer follow-up period, are warranted.

Limitations

This study does have some limitations. First, the concomitant procedures that were performed at the time of arthroscopy could have been responsible for some of the clinical improvements observed in our patients. Second, although we injected only a small number of stem cells, our results indicate that outcomes are positively related to the number of stem cells injected; in other words, patients would likely have seen greater benefits if our treatment had used a larger number. Unfortunately, the number of MSCs that can be isolated from the infrapatellar fat pad is fairly limited, and thus our major recommendation is to identify a cell source that will provide a higher yield of stem cells. Third, our treatments were delivered during a single injection, whereas it is possible that optimal results can only be obtained by giving patients more than one injection within a certain time period. Fourth, our study focused only on the effects of simultaneous treatment with both stem cells and PRP; additional work will be needed to measure the effects of pure stem cell injections, distinguish the effects of stem cells from those of PRP, and determine the proper use of costimulators. Fifth, we did not measure white blood cells in the PRP and therefore do not know how this variable might have influenced the efficacy of our treatments; this should be examined in the future. Last, because we collected data retrospectively, we were unable to perform either a routine second-look arthroscopy or a pathologic examination. In addition, we lost nearly 30% of our patients when these individuals declined to participate in follow-up visits.

Conclusions

The results of our study are encouraging and show that intra-articular injection of infrapatellar fat pad-derived

MSCs is effective for reducing pain and improving knee function in patients being treated for knee OA.

References

1. Beitzel K, McCarthy MB, Cote MP, et al. Rapid isolation of human stem cells (connective progenitor cells) from the distal femur during arthroscopic knee surgery. *Arthroscopy* 2012;28:74-84.
2. Raghunath J, Salacinski HJ, Sales KM, Butler PE, Seifalian AM. Advancing cartilage tissue engineering: The application of stem cell technology. *Curr Opin Biotechnol* 2005;16:503-509.
3. Murphy JM, Fink DJ, Hunziker EB, Barry FP. Stem cell therapy in a caprine model of osteoarthritis. *Arthritis Rheum* 2003;48:3464-3474.
4. Centeno CJ, Busse D, Kisiday J, Keohan C, Freeman M, Karli D. Regeneration of meniscus cartilage in a knee treated with percutaneously implanted autologous mesenchymal stem cells. *Med Hypotheses* 2008;71:900-908.
5. Centeno CJ, Busse D, Kisiday J, Keohan C, Freeman M, Karli D. Increased knee cartilage volume in degenerative joint disease using percutaneously implanted, autologous mesenchymal stem cells. *Pain Physician* 2008;11:343-353.
6. Buda R, Vannini F, Cavallo M, Grigolo B, Cenacchi A, Giannini S. Osteochondral lesions of the knee: A new one-step repair technique with bone-marrow-derived cells. *J Bone Joint Surg Am* 2010;92(suppl 2):2-11.
7. Lee KB, Hui JH, Song IC, Ardany L, Lee EH. Injectable mesenchymal stem cell therapy for large cartilage defects—A porcine model. *Stem Cells* 2007;25:2964-2971.
8. Sato M, Uchida K, Nakajima H, et al. Direct transplantation of mesenchymal stem cells into the knee joints of Hartley Strain guinea pig with spontaneous osteoarthritis. *Arthritis Res Ther* 2012;14:R31.
9. Yan H, Yu C. Repair of full-thickness cartilage defects with cells of different origin in a rabbit model. *Arthroscopy* 2007;23:178-187.
10. Koh YG, Choi YJ. Infrapatellar fat pad-derived mesenchymal stem cell therapy for knee osteoarthritis. *Knee* 2012;19:902-907.
11. Kellgren JH, Lawrence JS. Radiological assessment of osteo-arthrosis. *Ann Rheum Dis* 1957;16:494-502.
12. English A, Jones EA, Corscadden D, et al. A comparative assessment of cartilage and joint fat pad as a potential source of cells for autologous therapy development in knee osteoarthritis. *Rheumatology (Oxford)* 2007;46:1676-1683.
13. Wickham MQ, Erickson GR, Gimble JM, Vail TP, Guilak F. Multipotent stromal cells derived from the infrapatellar fat pad of the knee. *Clin Orthop Relat Res* 2003:196-212.
14. Kocher MS, Steadman JR, Briggs KK, Sterett WI, Hawkins RJ. Reliability, validity, and responsiveness of the Lysholm knee scale for various chondral disorders of the knee. *J Bone Joint Surg Am* 2004;86:1139-1145.
15. Borsa PA, Lephart SM, Irrgang JJ. Comparison of performance-based and patient-reported measures of function in anterior-cruciate-ligament-deficient individuals. *J Orthop Sports Phys Ther* 1998;28:392-399.
16. Peterfy CG, Guermazi A, Zaim S, et al. Whole-organ magnetic resonance imaging score (WORMS) of the knee in osteoarthritis. *Osteoarthritis Cartilage* 2004;12:177-190.

17. Reichenbach S, Rutjes AW, Nuesch E, Trelle S, Juni P. Joint lavage for osteoarthritis of the knee. *Cochrane Database Syst Rev* 2010;CD007320.
18. McIlwraith CW, Frisbie DD, Rodkey WG, et al. Evaluation of intra-articular mesenchymal stem cells to augment healing of microfractured chondral defects. *Arthroscopy* 2011;27:1552-1561.
19. Mishra A, Tummala P, King A, et al. Buffered platelet-rich plasma enhances mesenchymal stem cell proliferation and chondrogenic differentiation. *Tissue Eng Part C Methods* 2009;15:431-435.
20. Kruger JP, Hondke S, Endres M, Pruss A, Siclari A, Kaps C. Human platelet-rich plasma stimulates migration and chondrogenic differentiation of human subchondral progenitor cells. *J Orthop Res* 2012;30:845-852.
21. Kon E, Buda R, Filardo G, et al. Platelet-rich plasma: Intra-articular knee injections produced favorable results on degenerative cartilage lesions. *Knee Surg Sports Traumatol Arthrosc* 2010;18:472-479.
22. Marx RE. Platelet-rich plasma: Evidence to support its use. *J Oral Maxillofac Surg* 2004;62:489-496.
23. Phinney DG, Prockop DJ. Concise review: Mesenchymal stem/multipotent stromal cells: The state of transdifferentiation and modes of tissue repair—Current views. *Stem Cells* 2007;25:2896-2902.
24. Kuroda R, Ishida K, Matsumoto T, et al. Treatment of a full-thickness articular cartilage defect in the femoral condyle of an athlete with autologous bone-marrow stromal cells. *Osteoarthritis Cartilage* 2007;15:226-231.
25. Pittenger MF, Mackay AM, Beck SC, et al. Multilineage potential of adult human mesenchymal stem cells. *Science* 1999;284:143-147.
26. Aust L, Devlin B, Foster SJ, et al. Yield of human adipose-derived adult stem cells from liposuction aspirates. *Cytotherapy* 2004;6:7-14.
27. Bruder SP, Jaiswal N, Haynesworth SE. Growth kinetics, self-renewal, and the osteogenic potential of purified human mesenchymal stem cells during extensive subcultivation and following cryopreservation. *J Cell Biochem* 1997;64:278-294.
28. Dragoo JL, Samimi B, Zhu M, et al. Tissue-engineered cartilage and bone using stem cells from human infrapatellar fat pads. *J Bone Joint Surg Br* 2003;85:740-747.
29. Toghraie FS, Chenari N, Gholipour MA, et al. Treatment of osteoarthritis with infrapatellar fat pad derived mesenchymal stem cells in Rabbit. *Knee* 2011;18:71-75.